

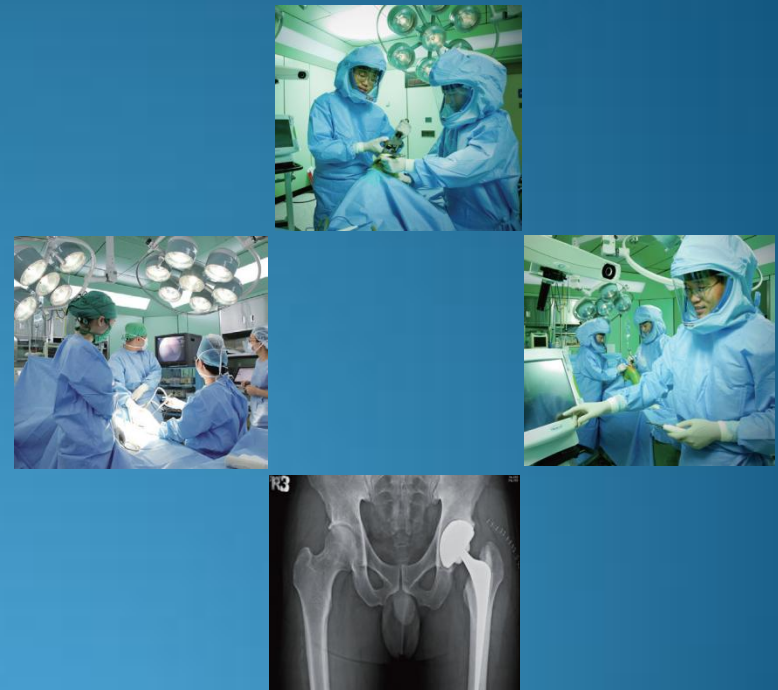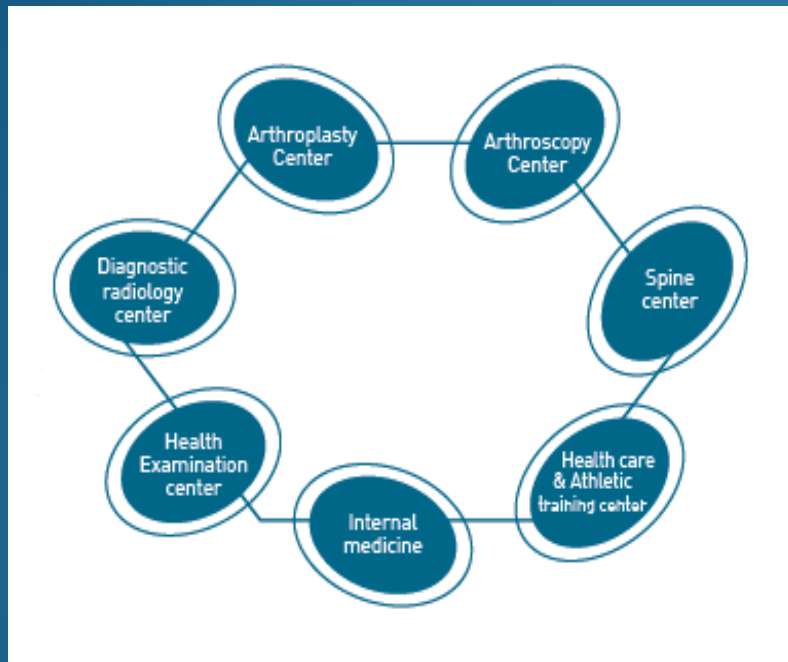
Wellton Hospital

2011. 07. 19



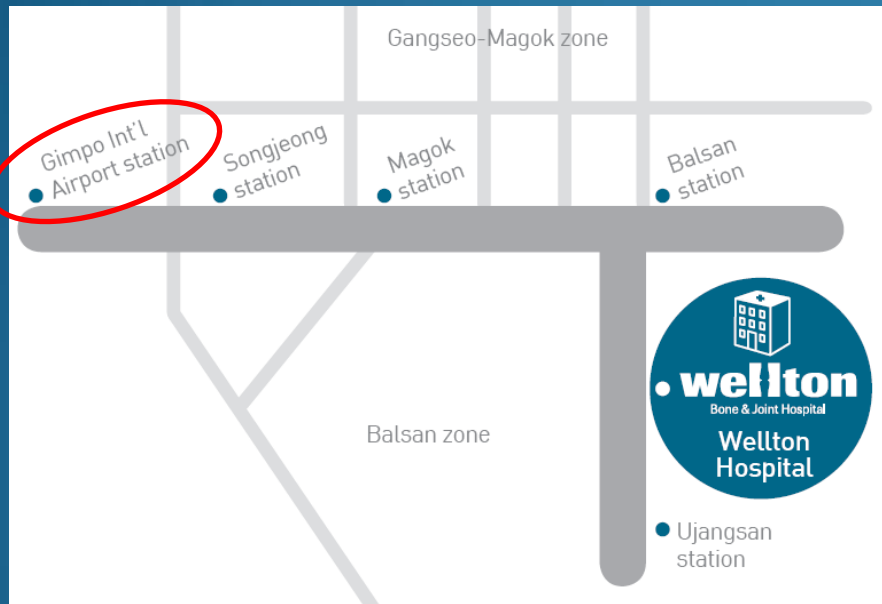
About Wellton

Wellton Hospital specializes in joints.



About Wellton

Directions



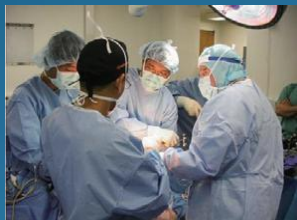Great accessibility
with fast traffic infra

Close to airport Magok area in Gangseo district is 5 minutes away from Kimpo Airport, and 30 minutes away from Incheon Airport.

Wellton's Specialties

Exchange with international medical teams

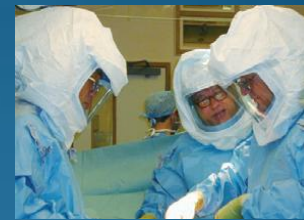Overseas Programs



Prof. Tria at St. Peters Univ. Hospital / MIS TKR / USA




Prof. Scuderi at Lenox Hill Hospital / MIS TKR / USA



Prof. Gie at Exeter Princess Elizabeth Hospital / Hip joint replacement Fellowship / UK

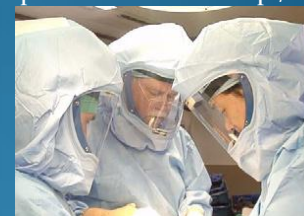Joint medical practice in Wellton



Prof. Scharf at Heidelberg Univ. Hospital, Computer navigation TKR, Germany

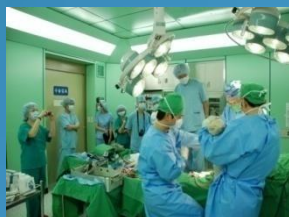

Prof. Sochart at Manchester Univ. Hospital, Hip Resurfacing Arthroplasty, UK



Prof. Dickey at St. Paul Hospital, MIS TKR, USA

International education in Wellton



Dr. Wong Yiu Chung at Yan Chai Hospital, HK



Dr. He Wei at Guangzhou University Hospital, China



Dr. LI Qiang at Central Hospital, China

Dr. Gu Guishan at Jilin University Hospital, China

Dr. ZHAN Chuan Taihe at China Medical University Hospital, China


Dr. GONG Taifang at Shiyan Hospital, China

Wellton's Specialties

Minimally Invasive Arthroplasty

- **MIS TKR**

- early rehabilitation and early recovery
- improve ROM




(by Johnson & Johnson)

- **MIS THR**

(Preserving short external rotator)

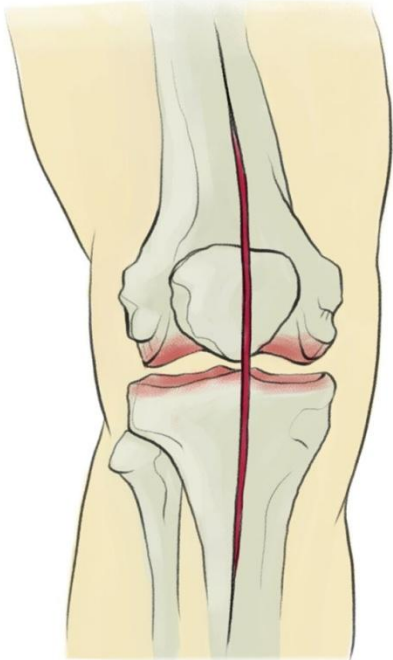
- prevent post OP hip dislocation
- early rehabilitation and early recovery



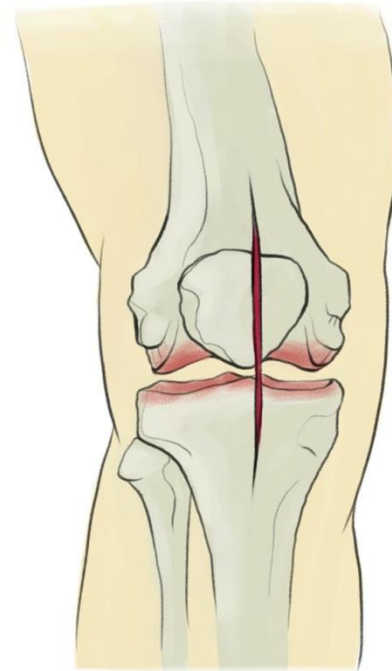
(by Stryker)

KNEE

Traditional and Minimal Incisions

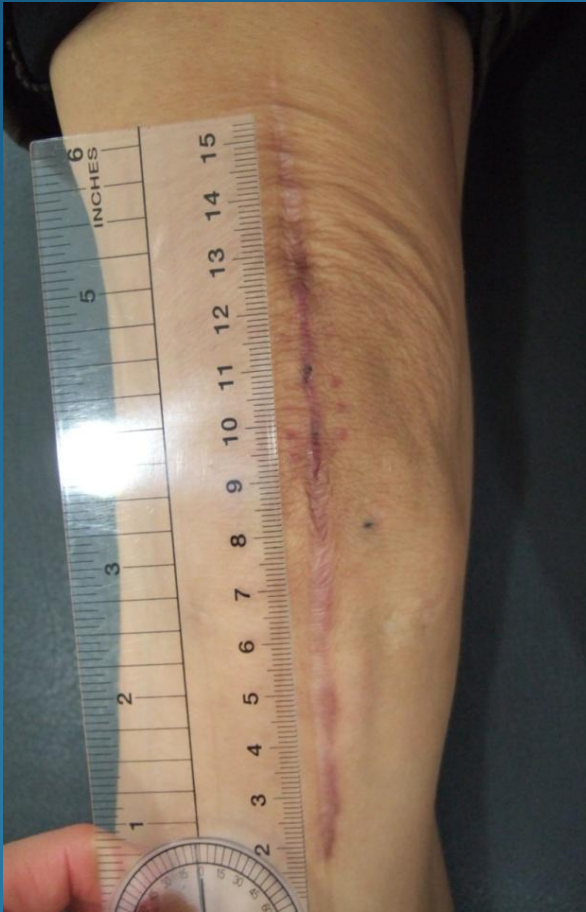

Traditional Incision

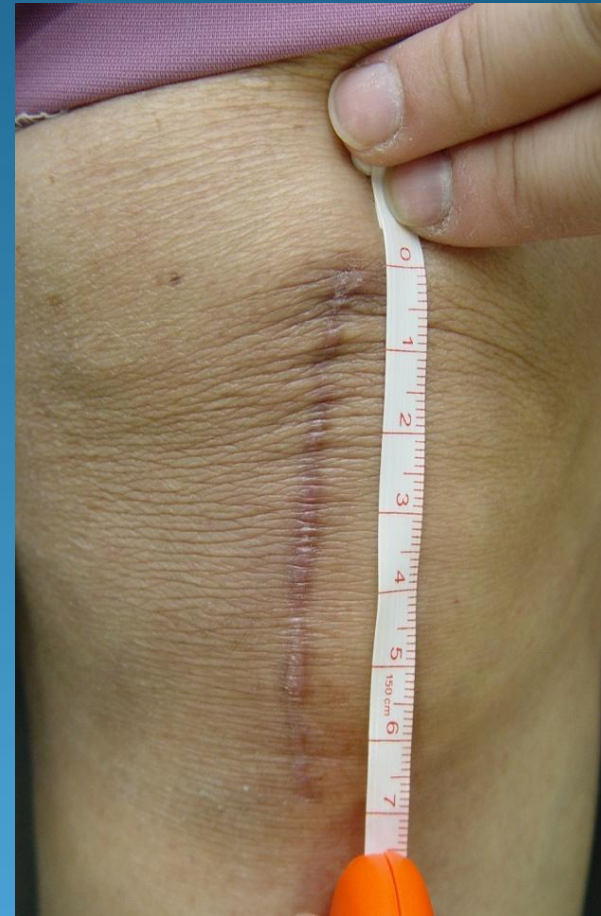

Mini Incision

Minimally Invasive TKR



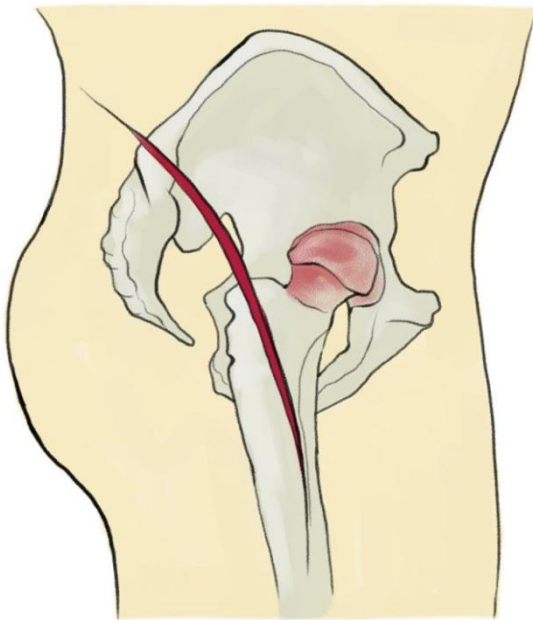
Traditional TKR



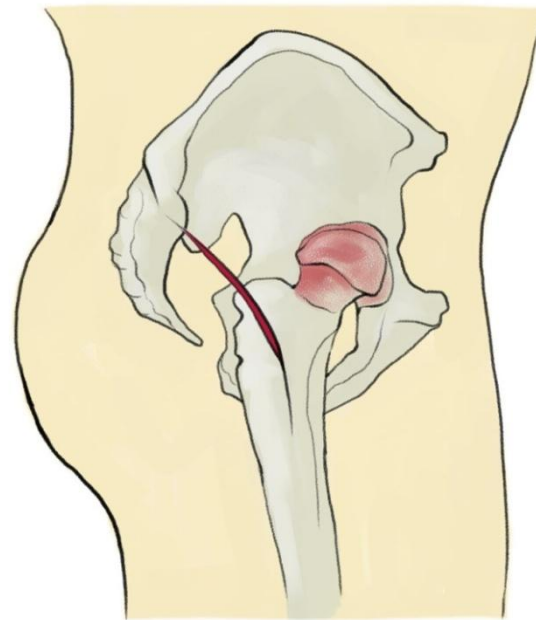
MIS TKR

HIP

Traditional and Minimal Incisions

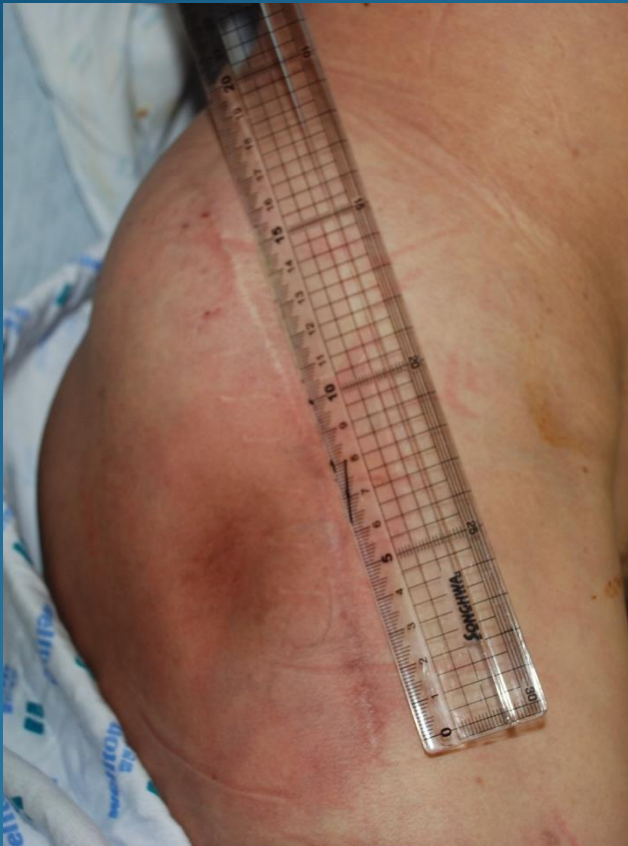

Traditional Incision

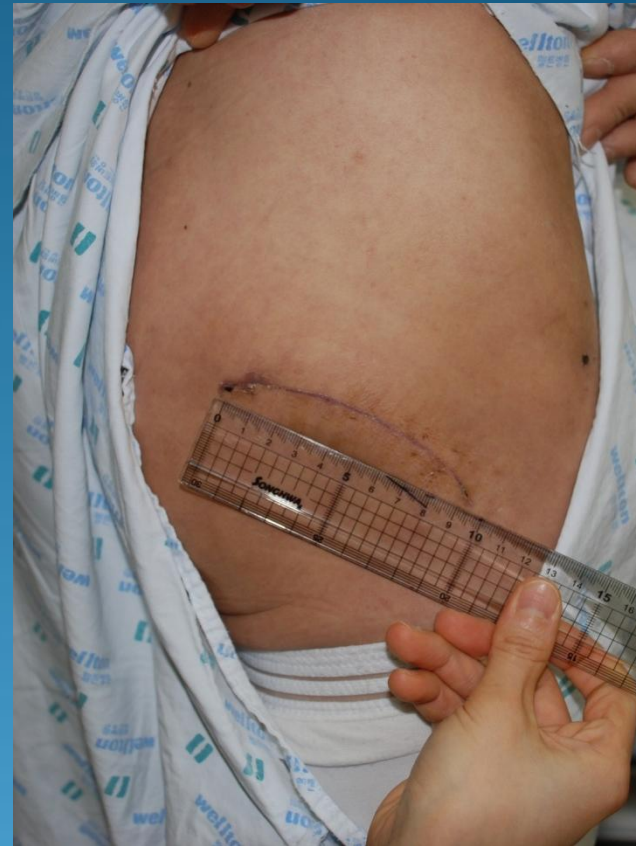

Minimal Incision

Minimally Invasive THR



Traditional Incision
(15-20cm)



Minimal Incision
(9-10cm)

Wellton's MIS TKR

Video Presentation



Before

(F / 84, Deg. O. A. Knee both)



After

(Rt-14 days, Lt-7 days)

Wellton's MIS THR

Video Presentation



4 hours After MIS THR

(M / 43, Deg. O. A. Hip
with acetabular dysplasia)



3 Days After MIS THR



7 Days After MIS THR

Conclusion

Small incision,

Preserving tendon,

Early rehabilitation!



Early Recovery!

Good Result!

